

CASE NOTE

Cytomegalovirus-associated ileal stricture in a preterm neonateRavisha M Srinivasjois,¹ Maina P Kava,¹ Anitha Thomas² and Shripada C Rao¹¹Department of Neonatal Paediatrics, KEM Hospital for Women and Princess Margaret Hospital for Children and ²Department of Pathology, Princess Margaret Hospital, Perth, Western Australia, Australia

Abstract: Gastrointestinal (GI) manifestations of post-natally acquired cytomegalovirus (CMV) in preterm neonates can vary from mild diarrhoea to severe necrotising enterocolitis. However, the suspicion of CMV-related GI disease remains low. Mild CMV disease localised to the GI tract may go undiagnosed initially until a more obvious complication such as strictures manifest. A case of CMV-associated enteritis in an extremely preterm neonate is presented. The diagnosis was established after the histopathology of the surgical specimen showed the presence of CMV inclusion bodies. Testing the stool specimen for CMV to establish the diagnosis when the pathology is limited to the GI tract is also discussed.

Key words: CMV; enteritis; NEC; neonate; preterm; stricture.

Congenital cytomegalovirus (CMV) infection presents with a multitude of clinical problems in neonates. Manifestations such as intrauterine growth retardation skin rashes, thrombocytopenia, chorioretinitis, abnormal liver function tests and intracerebral calcifications prompt investigations to establish CMV as the aetiology.¹

Post-natally acquired CMV infection can also result in significant morbidity especially in premature infants.² Diarrhoea, colonic strictures, ileal perforation and necrotising enterocolitis (NEC) are some of the reported gastrointestinal (GI) manifestations of post-natally acquired CMV infection.²⁻⁵

We present a case of post-natally acquired CMV-related enteritis resulting in ileal stricture in an extremely preterm neonate and discuss the possible role of rectal swab polymerase chain reaction (PCR) to enable early diagnosis.

Case History

A male neonate weighing 580 g was born at 23 + 5 weeks of gestation to a 29-year-old primigravida. The labour was precipitated by a combination of maternal sepsis and antepartum

Key Points

- 1 Ileal stricture is a rare complication of cytomegalovirus enteritis.
- 2 Testing the urine when the disease is limited to the gut can yield a false-negative result.
- 3 Testing the stool for cytomegalovirus should be performed when unusual gastrointestinal features are encountered.

Correspondence: Dr Ravisha M Srinivasjois, Department of Neonatal Paediatrics, KEM Hospital for Women, Bagot Road, Perth, WA 6008, Australia. Fax: 61 89340 1266; email: msravish@yahoo.com

Accepted for publication 25 July 2007.

haemorrhage. The mother was febrile for 7 days antepartum and intrapartum. She was treated with antibiotics and the blood culture was positive for *Bacteroides fragilis*.

The neonate was born by vaginal delivery. The Apgars were 4 and 7 at 1 and 5 min, respectively. He was intubated at birth for resuscitation and made an uneventful recovery from the hyaline membrane disease after surfactant administration and ventilation. Enteral feeds were started on the day 8 with fresh expressed mother's breast milk. The feeds were graded up cautiously to full oral feeds (150 mL/kg/day) by day 22. Between days 22 and 27 he developed loose stools, progressive metabolic acidosis, hypernatremia followed by abdominal distension and non-bilious vomiting progressing later to bilious aspirates. The stool tested negative for all the common viruses like rotavirus, enterovirus, adenovirus, norovirus and bacteria-like *Campylobacter*, *Salmonella*, *Shigella* and *Clostridium*. However, testing the stool for CMV PCR was not requested. Three samples of urine sent during this period were negative for CMV both on PCR and cultures. Abdominal X-rays showed dilated loops of bowel but no definite evidence of NEC. This was treated conservatively with bowel rest and antibiotics. Feeds were restarted 2 weeks later and full feeds were attained after 10 days. However, mild abdominal distension and intermittent episodes of feed intolerance continued to persist prompting treatment with short courses of antibiotics for 'suspect' sepsis and bowel rest on three occasions over the next 8 weeks.

On day 90 while on full feeds, the abdominal distension worsened. An abdominal X-ray revealed distended bowel loops with multiple fluid levels suggestive of distal intestinal obstruction. Laparotomy was performed and a small area of stricture approximately 20 cm from the ileo-caecal valve was excised followed by an end-to-end anastomosis. The histopathology of the ileum revealed ulceration, mixed inflammation and presence of scattered CMV inclusion bodies within the endothelial cells, suggestive of CMV enteritis. There was no vasculitis or

Table 1 Gastrointestinal manifestations of previously reported surgical cytomegalovirus cases

Cases no., author, year	Gestational age (weeks)	Birthweight (g)	Age at surgery (days)	Operative findings	Other clinical features
1. Huang <i>et al.</i> ⁵ (1996)	Term	3500	61	Perforation of terminal ileum	None
2. Stiskal <i>et al.</i> ⁶ (1997)	34	2695	31	Colonic stricture	None
3. Reyes <i>et al.</i> ⁷ (1997)	33	2200	49	Stricture of descending colon	Hearing impairment
4. Hakim <i>et al.</i> ⁸ (1997)	36	NA	22	Ileal ulceration	NA
5. Gessler <i>et al.</i> ³ (2004)	29	1490	10 weeks	Colonic stricture	None
6. Terry <i>et al.</i> ⁹ (2006)	30	NA	9 weeks	Inflamed ileocecal area, perforated appendix	None
7. Ekema <i>et al.</i> ⁴ (2006)	37	2490	34	Colonic stricture	Chorioretinitis
8. Shetty <i>et al.</i> ¹⁰ (2006)	27	490	65	Colonic stricture	None

NA, not available.

luminal thrombosis. The presence of CMV inclusions was confirmed on the biopsy using immunohistochemistry that revealed immunoreactivity for CMV antigens (Fig. 1).

Post-operative recovery was complete. Feeds were restarted on post-operative day 3 and full feeds were attained by post-operative day 7.

In view of the histopathological findings, tests for CMV were repeated. Urine, throat swab and respiratory secretions were all positive for CMV PCR and cultures. Rectal swab was positive for CMV PCR. CMV DNA was also detected on blood samples.

Placental examination revealed evidence of chorioamnionitis. However, there was no evidence of villitis or viral inclusions.

Eye examination did not reveal chorioretinitis. Head ultrasound and Liver function tests were normal. There was no thrombocytopenia. During the course of the NICU stay, he received eight packed cell transfusions. All were CMV antibody negative.

Discussion

Several similar cases with GI manifestations have been reported in the neonatal age group (Table 1). All the reported patients had initial GI symptoms ranging from difficulty in passing stools to a frank NEC-like illness. All the patients except Case 4 represented with acute intestinal obstruction prompting laparotomy or barium contrast followed by laparotomy long after the initial abdominal symptoms had resolved.

Our case presented initially with diarrhoea, hypernatremia, acidosis followed by abdominal distension and bilious aspirates in the fourth week of life. This episode was probably the beginning of the CMV enteritis culminating in ileal stricture subsequently.

During the initial episode of diarrhoea, stool specimen was tested for the common enteral viruses such as adenoviruses, rotaviruses, noroviruses and enteroviruses by PCR, but PCR testing of stool for CMV was not performed. However at this point, urine culture and PCR for CMV were negative on three occasions. This is possibly because the infection was limited only to the GI tract.

Diagnosis of post-natally acquired CMV is based on PCR and cultures from urine and respiratory tract and detection of

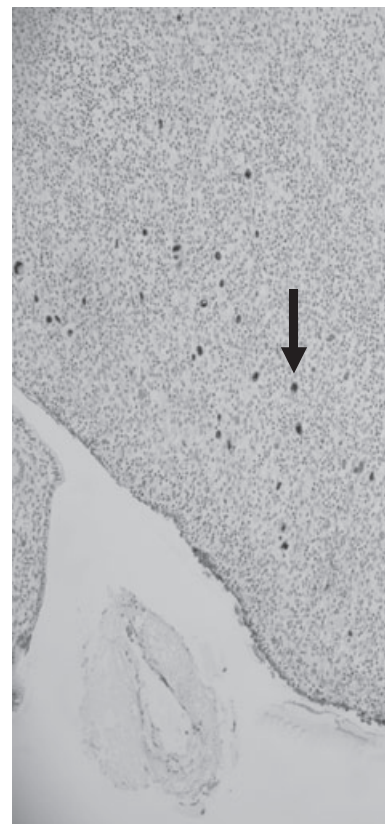


Fig. 1 Cytomegalovirus (CMV) inclusions demonstrated by immunohistochemical staining for CMV antibody in the ileal mucosa. Magnification $\times 40$.

CMV antigen from the blood specimen.^{11,12} Michel *et al.* have described the use of PCR from stool specimens to rule out intestinal CMV disease in immunocompromised adults.¹³ However, literature to this effect is lacking in the neonatal population. Demonstrating CMV inclusion bodies on the biopsy specimen is the gold standard to establish the diagnosis.¹⁴ But

intestinal biopsy being invasive is not possible in cases of suspected CMV enteritis in neonates. We suggest that a simple stool PCR examination for CMV should be considered in all unusual GI manifestation in the neonatal population.

Our case is most likely to be a post-natally acquired infection. The placental examination did not reveal the presence of CMV inclusion bodies and three urine cultures at 3–4 weeks of post-natal age were negative for CMV. The packed cells were all tested negative for CMV antibodies before transfusion. However, we did not test the mother's breast milk for CMV.

In summary, we would like to reinforce the importance of considering CMV infection in the differential diagnosis of unusual GI manifestations in premature infants. If the infection is localised only to the GI tract, testing the urine for CMV may not provide a positive result. Testing the stool and/or rectal swab by PCR and culture may help to identify CMV as the aetiological agent. The role of stool and rectal swab examination in the diagnosis of isolated enteritis without systemic involvement owing to CMV needs to be investigated further.

References

- Kylat RI, Kelly EN, Ford-Jones EL. Clinical findings and adverse outcome in neonates with symptomatic congenital CMV infection. *Eur. J. Pediatr.* 2006; **165**: 773–8.
- Cheong JLY, Cowan FM, Modi N. Gastrointestinal manifestations of postnatal cytomegalovirus infection in infants admitted to a neonatal intensive care unit over a five year period. *Arch. Dis. Child. Fetal Neonatal Ed.* 2004; **89**: F367–69.
- Gessler P, Bischoff GA, Weigand D, Essers B, Bossart W. Cytomegalovirus-associated necrotising enterocolitis in a preterm twin after breastfeeding. *J. Perinatol.* 2004; **24**: 124–6.
- Ekema G, Pedersini P, Milianti S, Ubertzani M, Minoli D, Manciana A. Colonic stricture mimicking Hirschsprung's disease: a localised cytomegalovirus infection. *J. Pediatr. Surg.* 2006; **41** (4): 850–2.
- Huang YC, Lin TY, Huang CS, Hseun C. Ileal perforation caused by congenital or perinatal cytomegalovirus infection. *J. Pediatr.* 1996; **129**: 931–4.
- Stiskal J, Jacquette M, Kaplan G, Ritterman R, Stavits R, Palder S. Congenital cytomegalovirus infection with gastrointestinal involvement. *J. Pediatr.* 1997; **131**: 168.
- Reyes C, Pereira S, Warden J, Sills J. Cytomegalovirus enteritis in a premature infant. *J. Pediatr. Surg.* 1997; **32**: 1545–7.
- Hakim A, Mimouni F, Payandeh F, Morawski J. Immunohistochemical staining in congenital cytomegalovirus induced ileal ulceration. *J. Pediatr.* 1997; **131**: 168–70.
- Terry NE, Fowler CL. Cytomegalovirus enterocolitis complicated by perforated appendicitis in a premature infant. *J. Pediatr. Surg.* 2006; **41**: 1476–8.
- Shetty A, Barnes R, Lazda E, Doherty C, Maxwell N. Cytomegalovirus – A cause of colonic stricture in a premature infant. *J. Infect.* 2007; **54**: e37–39.
- Neuberger P, Hamprecht K, Vochem M, *et al.* Case–control study of symptoms and neonatal outcome of human milk-transmitted cytomegalovirus infection in premature infants. *J. Pediatr.* 2006; **148**: 326–31.
- Liberek A, Rytleyska M, Szlagatys-Sidorkiewicz A *et al.* Cytomegalovirus disease in neonates and infants – clinical presentation, diagnostic and therapeutic problems – own experience. *Med. Sci. Monit.* 2002; **8**: CR815–20.
- Michel D, Marre E, Hampl W *et al.* Intestinal cytomegalovirus disease in immunocompromised patients may be ruled out by search for cytomegalovirus DNA in stool samples. *J. Clin. Microbiol.* 1995; **33**: 3064–7.
- Goodgame RW. Gastrointestinal cytomegalovirus disease. *Ann. Intern. Med.* 1993; **119**: 924–35.